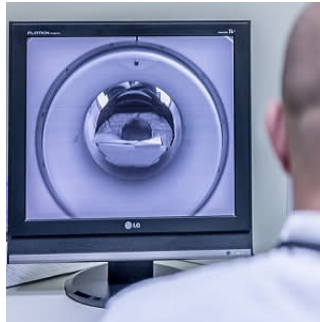


## The utility of MRI for diagnosing angiomyolipoma



According to new research, echogenic nonshadowing renal lesions larger than 4 mm seen at ultrasound should not be assumed to represent an angiomyolipoma (AML) without follow-up because a percentage of renal cell carcinomas will be missed. "Although certain ultrasound features can be useful in differentiating an AML from a renal cell carcinoma and CT is frequently diagnostic, an understanding of MRI is important because it can potentially detect lipid-poor AMLs," says the study published in the American Journal of Roentgenology.

Traditionally, ultrasound and CT have been the imaging modalities used in the diagnosis of AML. A reliable diagnosis of AML can be made when fat is unequivocally seen in a renal mass. This, however, may lead to false-negatives in the case of AMLs that show little or no fat, or when it is not possible to reliably assess a mass for visible fat because of its small size or where there is volume averaging of imaging voxels containing a combination of renal parenchyma and fat.

MRI has aided in the diagnosis of AML because of its ability to depict gross or macroscopic fat in nodules through the use of fat-suppression techniques and the use of in- and opposed-phase chemical-shift imaging. Although MRI is presently adopted in fewer institutions than ultrasound or CT, the study authors believe that knowledge of its applications in the diagnosis of AML is important to potentially avoid minimally invasive or surgical therapies in a percentage of patients who receive an incorrect diagnosis of renal cell carcinoma (RCC).

This retrospective study was conducted at a single radiology practice between August 2010 and April 2014. During this period, 5,018 renal ultrasound scans or abdominal ultrasound scans that included renal assessment were performed. All patients with a nonshadowing echogenic focus larger than 4 mm seen in the renal cortex were initially selected for the study, making the number of patients included initially 256. Follow-up data on 158 lesions in 132 patients were available. Confirmation of diagnosis was made with follow-up imaging or with histopathologic examination.

Data analysis revealed that 98 (62%) of the lesions were AMLs, eight (5.1%) were renal cell carcinomas, three (1.9%) were oncocytomas, 17 (10.8%) were artefacts, seven (4.4%) were fat, five (3.2%) were calculi, another eight (5.1%) were scars, and 12 (7.6%) were complicated cysts. The mean age of patients with AML was significantly lower than that of patients without AML (61.71 [SD, 13.25] years vs. 68.80 [SD, 17.85] years;  $p = 0.005$ ).

"There was a statistically significant association in our study between the sex of the patient and whether the patient had AML, with 88.8% of AMLs found in women and only 11.2% found in men ( $p < 0.001$ )," the authors note. "This supports the findings of Fittschen et al., who published the largest review of the demographics of AML in the literature."

Lipid-poor AMLs, which do not contain visible fat, account for around 5% of all AMLs. The pathologic definition of a lipid-poor AML is that they contain less than 25% fat per high-power field. They were difficult to diagnose radiologically before the introduction of MRI, leading to minimally invasive or surgical therapies. At MRI, lipid-poor AMLs are typically hypointense on T2-weighted images relative to the renal parenchyma.

Source: [American Journal of Roentgenology](#)

Image Credit: Pixabay

Published on : Tue, 14 Nov 2017