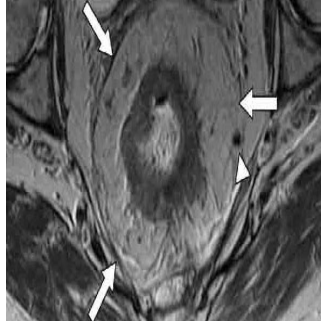


## The Critical Role of Imaging in Colon and Rectal Cancer Management



An international team of radiology experts has released a consensus statement highlighting the growing importance of imaging technology in the diagnosis, assessment and prognosis stratification of patients with colon and rectal cancers.

The study accompanies the recommendations for standardised, multidisciplinary management of colorectal diseases, which were released by the European Registration of Cancer Care (EURECCA) in 2013.

### Preoperative Imaging

Modern imaging techniques such as CT colonography are increasingly used as a complement to colonoscopy for patients whose colorectal examinations are performed with less than a 90% completion rate or for whom invasive procedures are impractical due to advanced age or poor health. The imaging technique is one of several, including high resolution MRI, frequently employed by physicians for their safety, sensitivity and specificity. Flow charts for the elective assessment of patients with either type of cancer were agreed upon by experts present at the consensus meeting (more than 80% agreement).

### Colon Cancer

CT colonography aids doctors in both the diagnosis and prognosis of patients with colon cancer. The newest procedures are more sensitive but less invasive than traditional tools employed by physicians for colon carcinoma diagnoses, such as air barium contrast enema and colonoscopy. While enemas are poorly tolerated and have become obsolete in colorectal cancer detection, colonoscopy preceding tissue biopsy remains the industry standard for diagnosis. However, the procedure is often incomplete and risky for many elderly and frail patients who are unfit for its potential consequences, including surgery to repair bowel perforation. In such cases, CT colonography is an alternative imaging tool highly effective for the detection of lesions greater than 1 centimeter in diameter. Subsequent to carcinoma diagnosis, imaging further assists physicians when it comes to tumour localisation and classifying patients along a spectrum of negative to positive prognoses. Assessment of the extent and stage of the disease by way of CT imaging can directly influence treatment type, especially in case of metastatic disease.

### Rectal Cancer

Imaging technology is also important prior to surgical treatment for rectal cancer.

As with colon carcinomas, staging influences decision making for doctors and patients, with MRI recommended for local analysis and CT applied to search for metastases in the pelvis, abdomen and chest. The application of such imaging tests for optimum disease management cannot be overstated, since it allows for patients with a poorer prognosis to benefit from some types of preoperative, nonsurgical treatments, which improve the odds of positive outcomes subsequent to surgery. Negative outcomes are associated with tumours found lower in the rectum, which are more likely to recur, and those without clear margins, since surgery is more difficult to plan and execute. Additional risk factors are the depth of tumour spread beyond the rectum into surrounding vasculature and the involvement of lymph nodes (nodal staging), assessed with MRI and high resolution MRI, respectively. According to the authors, modern imaging has greatly increased in sensitivity and specificity for more accurate distinctions of node negative and node positive disease, compared to previous methods of simple size judgment, ultrasound, CT scans and early MRI.

### Imaging and Implications

Management of colon and rectal cancer has advanced considerably in the last decade, with more noninvasive diagnosis and treatment methods, which are ever more safe, sensitive and specific. Consensus among radiology experts is that imaging will play an increasingly important role in the process, especially as the population ages and those who require colorectal screenings are deemed unfit for traditional testing. Of course, accuracy depends in large part on lesion size, and no imaging method is likely to replace colonoscopy for its ease of instant tissue extraction in the form of biopsy or polypectomy.

[Source: European Journal of Surgical Oncology](#)

Image credit: Google images

13 May 2014

Published on : Tue, 13 May 2014