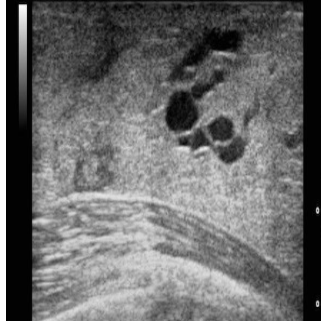


#RSNA14: Breast Ultrasound after Normal Mammo: Harm or Benefit?



On a population basis, more harm than good is caused by the addition of breast ultrasound after a negative mammographic work-up, cautioned Betty Tuong, MD, University of British Columbia, presenting a study at the Radiological Society of North America (RSNA) annual meeting in Chicago.

Abnormal screening mammograms are often further evaluated with spot compression views. If the abnormality does not persist on spot views, it is usually presumed that the lesion was artifactual from overlapping normal tissue, and the assessment is deemed negative. Multiple factors can lead to misinterpretation of the spot views and there may be false negative outcomes. There is a trend to perform breast ultrasound (US) despite a negative mammographic work-up. However, there is no scientific evidence to support this practice on a population basis. The objective of this study was to determine if the addition of US following negative spot views could detect breast cancers missed at initial assessment.

The investigators performed a retrospective chart review covering a 9.5 year period from 1 April 2004 to 31 October 2013, and evaluated the cases of patients with abnormal mammograms, negative follow-up spot views and concomitant breast US with respect to:

- final BIRADs assessment category;
- presence or absence of suspicious findings requiring biopsy;
- follow-up recommendations, including the type of examination and the time interval suggested.

For BIRADs 4/5 classifications the following elements were recorded:

- type of mammogram (initial screen, rescreen, surveillance or diagnostic study);
- mammographic breast density;
- ultrasound lesion characteristics and size;
- core biopsy and surgical pathology;
- follow-up imaging and management initiated by a benign biopsy to a final diagnosis of benign or cancerous.

Out of 3867 cases who received spot mammogram and breast US, 1860 patients were enrolled classified mostly as BIRADs 1/2, followed by BIRADs 3, with BIRADs 4/5 making up 29 percent of cases (55).

Of the BIRADs 4/5 cases, the mammographic abnormalities brought back for recall included asymmetry (25), focal asymmetry (18), architectural distortion (8) or a mass (4). The sonographic abnormalities requiring biopsy included a region of shadowing (23) or a mass (32). The average size of the sonographic abnormality was 1.1 cm. Final pathology was invasive ductal carcinoma (4), ductal carcinoma in situ (2), fibrocystic change (10), fibroepithelial lesion (4), radial scar (2), fat necrosis (2), benign papillary lesion (2) and benign breast tissue (29). The prevalence of a mammographically occult cancer that could be detected by US was 0.3 percent.

For the patients with benign core biopsies (49/55), 56 additional imaging studies were recommended and were performed up to a two year period, to a final benign diagnosis. 210 patients who underwent breast US received a final BIRADs 3 recommendation, leading to a total of 255 additional imaging studies performed up to three years. All these cases were benign when follow-up was completed. No malignancies were found in any lesions initially discovered and classified as BIRADs category 3.

The average age of patients in the study was 56 years, and most of the index mammograms were rescreens (40/55). None had fatty breast tissue, and most (30/55) had heterogeneously dense breast tissue.

Tuong said that as their study found a very low prevalence of a mammographically occult cancer that can be detected by US, it supported the view that the harm of additional biopsies and imaging tests outweighs the benefit, and additional US should not be performed routinely. However, she added, it would be conceivable that if a highly suspicious mammographic abnormality is present on an index mammogram and resolves on spot compression views a follow-up breast ultrasound may be valuable.

Responding to audience questions on whether they got far enough back on the spot view as the spot could push the lesion backwards out of the field of view, Tuong confirmed that the cases were independently reviewed by three radiologists who agreed that it was negative.

Claire Pillar
Managing Editor, HealthManagement

© For personal and private use only. Reproduction must be permitted by the copyright holder. Email to copyright@mindbyte.eu.

Image source: Wikimedia Commons © Nevit Dilmen

Published on : Thu, 4 Dec 2014