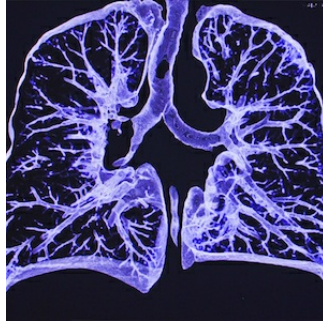


## Radiologists on Coronavirus Frontline



---

Radiologists are expected to be among the first healthcare professionals to be involved in the diagnosis of 2019-nCoV through chest CT. Early disease recognition is critical not only for prompt treatment, but also for patient isolation and effective public health containment and response.

To provide radiologists with more information about the new respiratory illness caused by the new virus, Radiology published an online article named "[CT Imaging of the 2019 Novel Coronavirus \(2019-nCoV\) Pneumonia](#)".

You might also like: [ESR Offers Online ECR Congress in Face of Wuhan Virus](#)

The report includes chest CT images of pneumonia infected with 2019-nCoV provided by physicians from The First Hospital of Lanzhou University, Lanzhou, China. Based on their findings, the physicians note the appearance of multiple ground-glass opacities in bilateral lungs, which is one of the common findings of 2019-nCoV.

In mainland China, the number of infections with 2019-nCoV seems to increase by the day, as the virus is reportedly spreading from person-to-person in various parts of that country.

The complete clinical picture with regard to 2019-nCoV is still not fully clear. Common symptoms reported for patients with 2019-nCoV include mild to severe respiratory illness with fever, cough, and difficulty breathing.

Source: [RSNA](#)

Image credit: [Radiology](#)

Published on : Tue, 4 Feb 2020