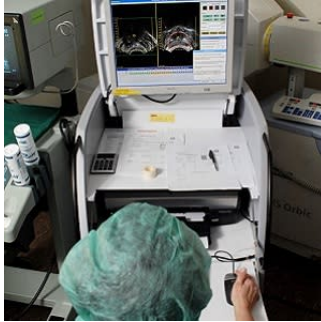

Prostate mpMRI detects local recurrence after LDR brachytherapy



Low dose rate (LDR) brachytherapy is commonly used for the treatment of prostate cancer. Although most patients who receive LDR brachytherapy for prostate cancer will be cured of their disease, biochemical recurrence occurs in 3%–13% of men undergoing monotherapy. New research demonstrates the efficacy of multiparametric magnetic resonance imaging (mpMRI) for detecting local recurrence of prostate cancer after LDR brachytherapy. The study is published in the journal *Diagnostic and Interventional Radiology*.

MRI has an increasing role in the diagnosis and management of prostate cancer. However, because of concern for MRI artefact caused by brachytherapy seeds, mpMRI is rarely used in the setting of biochemical recurrence following this treatment. Researchers hypothesised that mpMRI would be effective in identifying locally recurrent cancer in this setting; they conducted a multireader study to evaluate the diagnostic performance of mpMRI for local recurrence following LDR brachytherapy.

In this study, 19 patients with biochemical recurrence after LDR brachytherapy underwent 3T endorectal coil mpMRI with T2-weighted imaging, dynamic contrast-enhanced imaging (DCE) and diffusion-weighted imaging (DWI) with pathologic confirmation. Prospective reads by an experienced prostate radiologist were compared with reads from four radiologists of varying experience. Readers identified suspicious lesions and rated each MRI detection parameter.

The researchers reported these key findings:

- Pathologically confirmed recurrence was found in 15 of 19 patients. LDR brachytherapy recurrences identified by mpMRI were frequently located in the transition zone (41%) and seminal vesicles (32.3%).
- At the patient level, mpMRI correctly detected pathologically confirmed lesions with a sensitivity of 88% for all lesions and a specificity of 75% for highly suspicious lesions.
- At the lesion level, mpMRI demonstrated a high cancer-detection rate of 78.7% for highly suspicious lesions.
- Radiologists of varying experience demonstrated 54.4% agreement when detecting recurrent cancers at the patient level.

mpMRI includes a number of sequences and the researchers say it is possible that the artefact introduced by brachytherapy seeds may further alter the performance of certain sequences while minimally impacting others. Radiation-induced changes have been demonstrated to cause diffuse T2-weighted signal hypointensity, limiting the diagnostic capability of T2-weighted imaging.

"Indeed, in our study T2-weighted imaging did not perform as well as other parameters, but interestingly, DWI trended towards a higher cancer detection rate at 70% compared with 66.6% for T2-weighted imaging and 64.9% for DCE," the researchers write.

Although artefact is observed, mpMRI can still be performed and may provide useful information following LDR brachytherapy, according to the researchers, noting that patterns of recurrence suggest anterior prostate as well as seminal vesicles should be areas of focus for optimising initial diagnosis and treatment as well as detecting recurrence.

For brachytherapy practitioners, understanding the patterns of local recurrence after treatment may inform patient selection or alter implant techniques in certain cases to optimise dosimetry.

Source: [Diagnostic and Interventional Radiology](#)

Image Credit: [Rock mc1](#)

Published on : Tue, 23 Jan 2018