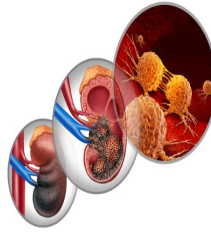


---

## Exploring the Role of PSMA PET/CT Imaging in Renal Cell Carcinoma



---

Renal cell carcinoma (RCC) is a significant global health issue, constituting a sizable portion of cancer cases and presenting challenges in early detection due to its asymptomatic nature. Imaging techniques like CT and MRI are crucial for diagnosing and staging RCC, but they may miss small or low-grade metastatic lesions. As a result, there's a need for more sensitive methods to detect metastatic RCC early on. Recent interest has focused on prostate-specific membrane antigen (PSMA) targeted PET imaging, initially developed for prostate cancer. PSMA, found in prostate cancer cells and in the neovasculature of various solid tumours, including RCC, shows potential as a marker for imaging RCC. PSMA expression varies among RCC subtypes, with clear cell RCC (ccRCC) showing the highest levels. Studies have explored the use of PSMA-targeted PET imaging, predominantly using 18F-labeled tracers due to their longer half-life and better resolution compared to 68Ga. These studies have shown promising results in detecting primary RCC and restaging metastatic or recurrent RCC. However, there's a lack of comprehensive analysis across available literature. To address this gap, [a systematic review and meta-analysis](#) published in the Journal of Nuclear Medicine were conducted to evaluate the role of PSMA PET/CT in staging and restaging RCC. The findings aim to provide a clearer understanding of the effectiveness of PSMA PET/CT in detecting RCC at various stages and guiding its management.

### Systematic Review and Meta-Analysis of PSMA PET/CT Imaging in Renal Cell Carcinoma

The systematic literature review was conducted on August 25, 2023, adhering to the Preferred Reporting Items for Systematic Review and Meta-Analyses (PRISMA) guidelines. The search encompassed databases such as PubMed and Embase, as well as abstract proceedings from significant scientific meetings like the Society of Nuclear Medicine and Molecular Imaging and the European Association of Nuclear Medicine. No limitations were imposed on language, publication date, or publication status.

The search strategy involved a combination of keywords focusing on renal cell carcinoma (RCC) and prostate-specific membrane antigen (PSMA). Eligible studies included clinical investigations exploring the utility of PSMA PET/CT imaging in staging or restaging patients with RCC, irrespective of their histological subtype. The index tests considered in these studies comprised 18F-DCFPyL, 18F-PSMA-1007, 68Ga-PSMA-11, or 68Ga-P16-093 PET/CT scans.

During the selection process, records were initially screened based on their titles and abstracts to exclude review articles, editorials, and irrelevant citations. Full texts of potentially relevant publications were then retrieved and independently evaluated by two authors against predefined inclusion criteria.

Data extraction from the included studies involved collecting various details such as bibliographic information, patient demographics, tumour characteristics, and detection rates associated with PSMA PET/CT imaging. Subsequent statistical analysis and data synthesis were performed using R software. A lesion-based meta-analysis of single proportions was conducted to estimate the pooled detection rate of PSMA PET/CT in RCC patients. Subgroup analyses were conducted for specific radiotracers and for comparisons with conventional imaging modalities, where applicable.

Heterogeneity among the included studies was assessed using the I<sup>2</sup> index, with random-effect assumptions employed to synthesise meta-analytic data in instances of high heterogeneity. Additionally, funnel plots were utilised to evaluate publication bias within the reviewed literature.

### Insights into Staging and Restaging Strategies

From the comprehensive search, 145 articles were identified, with 31 undergoing full-text review after initial screening. Ultimately, nine articles were included in the final meta-analysis, involving 152 patients (133 ccRCC, 19 other RCC subtypes). These studies provided data on the lesion-level detection rate of PSMA PET/CT for staging or restaging RCC. The estimated pooled lesion-level detection rate of PSMA PET/CT

with any radiotracer was 0.83 (95% CI, 0.67–0.92), with high heterogeneity ( $I^2 = 81\%$ ).

In the subgroup analysis for restaging of metastatic or recurrent RCC, seven articles involving 90 patients (87 ccRCC, three other subtypes) were included. The estimated pooled lesion-level detection rate of PSMA PET/CT with any radiotracer in this context was 0.87 (95% CI, 0.73–0.95), with substantial heterogeneity ( $I^2 = 76\%$ ). When considering only ccRCC cases, the pooled detection rate remained high at 0.85 (95% CI, 0.64–0.95).

For staging or evaluation of primary RCC lesions, three studies with 62 patients (48 ccRCC, 14 other subtypes) reported data on  $^{68}\text{Ga}$ -PSMA PET/CT. The pooled detection rate for primary RCC lesions was 0.74 (95% CI, 0.57–0.86), with moderate heterogeneity ( $I^2 = 38\%$ ). This indicates that approximately 74% of primary RCC lesions were PSMA-positive based on the analysis.

### Implications for Clinical Practice

The study systematically reviewed literature on PSMA PET/CT imaging in staging or restaging RCC, conducting a meta-analysis when feasible. It's the first meta-analysis assessing the detection rate of PSMA PET/CT in this context. Results indicate its potential in staging primary RCC lesions (pooled detection rate: 0.74, 95% CI: 0.57–0.86) and restaging metastatic or recurrent RCC (pooled detection rate: 0.87, 95% CI: 0.73–0.95). Both  $^{68}\text{Ga}$ -based and  $^{18}\text{F}$ -based PSMA radiotracers showed high detection rates for evaluating metastatic RCC.

High heterogeneity among studies ( $I^2 > 75\%$ ) stemmed from various study types, radiotracer differences, mixed patient populations, and limitations like lack of pathological confirmation of lesions. Notably, pulmonary nodules, due to motion and size, influenced heterogeneity. Excluding certain studies improved heterogeneity. Initial studies demonstrated the effectiveness of PSMA PET/CT in ccRCC, the most common RCC subtype, especially for evaluating metastatic disease.

Direct comparisons with conventional imaging favoured PSMA PET/CT, showing higher detection rates and sensitivity, particularly in ccRCC. Despite limitations, like study size and retrospective nature, PSMA PET/CT shows promise in RCC detection and characterisation. Prospective trials with larger sample sizes and rigorous inclusion criteria are warranted to validate its diagnostic efficacy, especially for high-risk patients and those with oligometastatic disease.

While based on small-scale studies with high heterogeneity, the findings support the potential utility of PSMA PET/CT in RCC staging and restaging, particularly for metastatic or recurrent disease.

Source: [Journal of Nuclear Medicine](#)

Image Credit: [iStock](#)

Published on : Tue, 28 May 2024