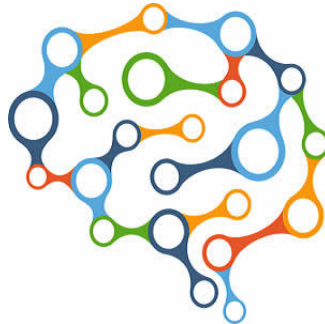


Detecting Consciousness in Patients with Severe TBI



Functional magnetic resonance imaging (fMRI) and electroencephalography (EEG) can be used to identify ICU patients with severe traumatic brain injuries who have a level of consciousness not revealed by the standard bedside neurological examination. Early detection of consciousness and brain function in the intensive care unit could alter time-sensitive decisions about withholding life-sustaining care, according to the study published in the journal *Brain*.

Patients with acute severe traumatic brain injury (TBI) may recover consciousness before self-expression. Without behavioural evidence of consciousness at the bedside, clinicians may render an inaccurate prognosis, increasing the likelihood of withholding life-sustaining therapies or denying rehabilitative services. Task-based functional fMRI and EEG techniques have revealed covert consciousness in the chronic setting, but these techniques have not been tested in the ICU.

The current study by Massachusetts General Hospital (MGH) investigators enrolled 16 patients cared for in MGH intensive care units after severe TBI. Upon enrolment, eight were able to respond to language, three were classified as minimally conscious without language response, three classified as vegetative and two as in a coma. fMRI studies were conducted as soon as patients were stable enough for the procedure, and EEG readings were taken soon afterwards, ideally but not always within 24 hours. A group of 16 healthy age- and sex-matched volunteers underwent the same procedures as a control group.

The screenings were taken under three experimental conditions. To test for a mismatch between participants' ability to imagine performing a task and their ability to physically express themselves – what is called cognitive motor dissociation – participants were asked to imagine squeezing and releasing their right hand while in the fMRI scanner and while EEG readings were being taken. Since it is known that certain areas of the brain can respond to sounds even when an individual is asleep or under sedation, participants also were exposed to brief recordings of spoken language and of music during both fMRI and EEG screenings. Those tests were designed to detect activity in areas of the brain that are part of the higher-order cortex, which interprets the simple signals processed by the primary cortex – in this instance not just detecting a sound but potentially recognising what it is.

Of the eight patients who were classified as unable to respond to language in the bedside examination, evidence of covert consciousness based on the hand-squeeze exercise was found in four, including the three originally classified as vegetative. In two additional patients, higher-order cortex activity was seen in response to either language or music. While higher-order cortical activity doesn't prove that a patient is conscious, finding a response in those structures could have implications for a patient's eventual recovery, explains Brian Edlow, MD, of the Center for Neurotechnology and Neurorecovery in the MGH Department of Neurology, co-lead and corresponding author of the study.

Dr. Edlow also stresses that negative responses to these tests should not be taken as predicting a low likelihood of recovery. Overall, the study found no associations between early brain responses and long-term outcomes, which could relate to the small size of the study or the fact that several patients were sedated during the fMRI and EEG tests.

The study notes that the low sensitivity of the right-hand squeeze motor imagery paradigm for detecting behavioural evidence of language supports the need for development of motor imagery tasks that have lower cognitive demands and/or tasks whose responses are more robustly detected by functional MRI and EEG.

"Much more work needs to be done to determine the utility of these techniques for detecting consciousness in patients with severe traumatic brain injuries," Dr. Edlow said, adding that the MGH team is working on improving the accuracy of these tests.

Source: [Brain; Massachusetts General Hospital](#)
Image Credit: Pixabay

Published on : Tue, 25 Jul 2017