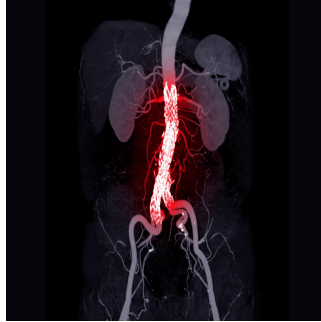


Aneurysm Growth Detection: Radiomic Features of Perivascular Adipose Tissue



Abdominal aortic aneurysms (AAA) represent a critical condition characterised by localised dilation of the aorta with the risk of rupture and life-threatening haemorrhage. Surgical interventions like endovascular aneurysm repair (EVAR) are recommended when these aneurysms grow significantly. Although EVAR is a minimally invasive and widely used approach to treat AAA, there remains a need for long-term follow-up to monitor potential aneurysm growth after the procedure. The perivascular adipose tissue (PVAT) surrounding the aorta plays a crucial role in vascular biology and has been associated with cardiovascular diseases. Radiomics, which involves extracting high-dimensional features from medical images, presents an opportunity to assess PVAT characteristics and potentially predict AAA growth after EVAR. A recent review published in *Insights into Imaging* examines a study that explores the relationship between PVAT radiomic features and AAA growth, comparing the efficacy of clinical-radiological models to predict aneurysm progression.

Role of PVAT in AAA Growth

AAAs are aortic dilations greater than 3 cm, with risks primarily stemming from rupture and haemorrhage. EVAR, a minimally invasive technique, is safer than traditional open surgery. Still, post-procedural monitoring is essential to identify aneurysm growth, a potential indicator of complications such as endoleaks, endotension, or other hemodynamic changes. Understanding factors contributing to post-EVAR aneurysm growth can significantly improve long-term patient outcomes.

Recent research has highlighted a possible link between obesity and AAA development, suggesting that PVAT plays a crucial role in vascular pathology. PVAT, which surrounds blood vessels, is not merely passive but actively secretes adipokines, cytokines, and growth factors. These substances can either inhibit or promote cardiovascular disease progression, and PVAT infiltration into the vessel wall may contribute to aneurysm development through inflammatory processes. Moreover, PVAT around the aorta has been associated with aortic remodelling, implying that local fat deposits may influence vascular changes. Given this complex interplay, radiomic analysis of PVAT might provide valuable insights into aneurysm progression and aid in the stratification of patients for post-EVAR follow-up.

Radiomic Analysis and Differentiating AAA Growth

In this study, 79 patients with sub-renal AAAs who underwent EVAR and regular post-operative follow-up were retrospectively analysed. The patients were categorised into two groups based on aneurysm growth, with "growing" defined as a greater than 2% increase in aneurysm volume compared to the initial post-EVAR follow-up. PVAT regions were segmented from enhanced CT scans using specialised software, and a series of radiomic features were extracted, including shape, histogram-based, and texture-based characteristics.

Statistical analysis revealed that growing AAAs exhibited a higher surface area to volume ratio in the PVAT region than non-growing AAAs. This finding supports the hypothesis that the close adherence of fat to blood vessels in growing AAAs might facilitate further infiltration or secretion of PVAT factors that drive growth. Additionally, the texture of PVAT in growing AAAs displayed higher heterogeneity, characterised by low dependence and high dispersion, as evidenced by various texture features like grey-level co-occurrence and dependence matrices. These differences suggest that the internal composition of PVAT in growing AAAs is more heterogeneous than in non-growing AAAs.

Notably, the study also identified that traditional clinical parameters, including levels of low-density lipoprotein (LDL), high-density lipoprotein (HDL), and total cholesterol (TC), differed between growing and non-growing AAAs, indicating that lipid profiles may play a role in aneurysm growth. However, when combined with the radiomic features of PVAT, the predictive model improved substantially, demonstrating the added value of integrating radiomic analysis into clinical practice.

Clinico-Radiological Model Performance and Implications for Follow-Up

The predictive performance of different models for assessing AAA growth was compared, including one based solely on radiomic features, one based on clinical features, and an integrated clinical-radiological model. The clinico-radiological model achieved an area under the curve (AUC) of 0.78, indicating a robust predictive ability with a specificity of 87%, superior to the individual radiomic and clinical models (both AUC = 0.69).

This suggests that combining PVAT radiomic features with clinical data offers a more accurate tool for predicting aneurysm growth after EVAR.

The model's ability to achieve high specificity implies its utility in minimising false positives and reducing unnecessary interventions for non-growing AAAs. The improved classification of growing versus non-growing AAAs using the clinical-radiological model highlights the potential of radiomic features to inform clinical decision-making and enhance post-EVAR monitoring. Early identification of AAAs' progression allows interventions to be made in time, potentially improving the prognosis for the patients and reducing the risk of complications.

Given these findings, integrating PVAT radiomic analysis into the standard follow-up protocol for EVAR patients could lead to better risk stratification and individualised surveillance. Moreover, future research could expand on this by developing comprehensive models incorporating radiomic features of the aneurysm sac, intraluminal thrombus, and additional clinical factors to improve the predictive accuracy for AAA growth.

Radiomic analysis of PVAT provides a novel approach to predicting AAA growth after EVAR. The study demonstrates that growing AAAs have distinct radiomic characteristics, including a higher surface area to volume ratio and more heterogeneous texture, which can be used to classify aneurysm growth status accurately. Combining these radiomic features with traditional clinical parameters, the integrated clinico-radiological model offers a valuable tool for guiding post-EVAR follow-up and enhancing patient management. Such advanced imaging analysis can significantly improve outcomes for AAA patients by allowing for more personalised monitoring and early intervention strategies. As radiomics continues to evolve, further studies are needed to refine these models and establish them as a standard component of AAA care.

Source: [Insights into Imaging](#)

Image Credit: [iStock](#)

Published on : Wed, 2 Oct 2024