


Advanced MRI for Stiff Heart Syndrome



Academics at UCL have developed an advanced form of cardiac MRI to measure the effectiveness of chemotherapy in patients with stiff heart syndrome.

Stiff heart syndrome occurs when plaques of protein build up in the heart muscle. This affects the heart's ability to pump blood. Without appropriate treatment, this condition can lead to heart failure and death. There are about 4000 to 6000 amyloidosis patients in the U.K. However, many more remain undiagnosed. The condition is more prevalent in men.

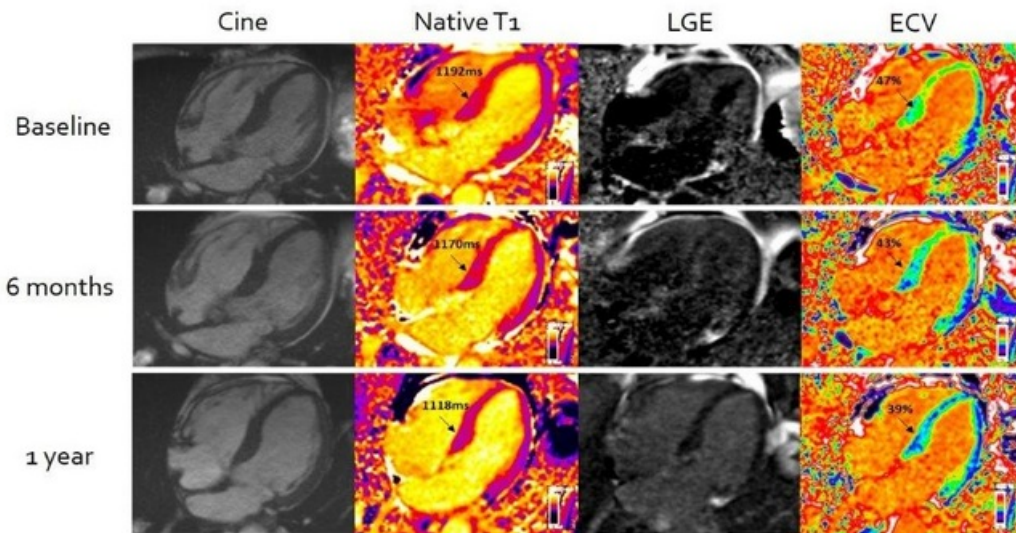
Assessment of stiff heart syndrome can be challenging. Clinicians can detect the presence of amyloid in the heart, but there is no safe test to measure the amount. Thus, it is difficult for clinicians to measure the therapeutic effect of chemotherapy, which is the first line of treatment in these patients.

Currently, patient response is assessed through indirect biological markers that do not measure the amount of cardiac amyloid. Clinicians find these markers less useful when trying to assess second-line chemotherapy treatments.

The team at UCL has been developing and refining Cardiovascular Magnetic Resonance (CMR) Extracellular Volume Mapping (ECV) for amyloid. This non-invasive technique enables clinicians to measure the *presence* and *amount* of amyloid protein using MRI.

The technology has been used for the first time to evaluate the success of chemotherapy treatment by assessing cardiac amyloid regression or progression. The study included 176 patients with light-chain cardiac amyloidosis. They underwent CMR scans with ECV mapping at diagnosis and then again at six, 12 and 24 months after starting chemotherapy.

With this advanced cardiac MRI technique, researchers could accurately measure the amount of amyloid protein in the heart and the changes in response to chemotherapy on repeat scans. This allowed them to detect which patients would have a better or worse prognosis.



Cardiac amyloidosis improvement demonstrated by Cardiovascular Magnetic Resonance (CMR) Extracellular Volume Mapping (ECV) for amyloid. Baseline scan on top row; after six months of chemotherapy mid row; and one year after chemotherapy bottom row. There are progressive reductions in CMR (identified as T1 - column two) and ECV (column four) over the course of the treatment. Source: UCL.

The researchers found that nearly 40% of patients had a substantial reduction in amyloid deposition. This shows how effective chemotherapy could be.

This tool can provide valuable information to clinicians as it enables them to know the amount of amyloid. This can help guide treatment options and decide the timing and protocol of second-line chemotherapy treatments.

Source: [University College London](https://www.ucl.ac.uk)

Image Credit: iStock

Published on : Tue, 2 Aug 2022